

# Hydraulic and Hydrophobic Impressions

Jeffrey C. Hoos, DMD; Gary J. Kaplowitz, DDS, MA, MEd

As appeared in Dentistry Today, October 1998

There have been many significant developments in dental materials and technology, enabling dentists to replace missing teeth with metal-free fixed prosthetics. In many cases, this kind of treatment plan is practical and a viable alternative to conventional framework bridges. Patients also desire avoiding tooth reduction or invasive procedures, which is required with conventional fixed prosthetics. They also want to avoid the unaesthetic display of metal wings, common with resin-bonded fixed common-width Maryland bridges.

## CLINICAL CASE

A 35-year-old male presented with a failing Maryland bridge replacing a missing mandibular second premolar (Figure 1). There was carious enamel along the margins of the metal wings on the first premolar and first molar. Because of the extent of the carious enamel, the patient was advised to have the Maryland bridge removed, allowing the full extent of the caries to be identified and excavated. The Maryland bridge had debonded and been recemented once before during its 14 years. Neither metal wing was loose. The patient was also dissatisfied with the extent to which the metal wings were visible and wanted them replaced with a more aesthetic prosthesis. He had few restorations in his other teeth, excellent oral hygiene, and was very concerned about further invasive treatment involving the first molar and first premolar.

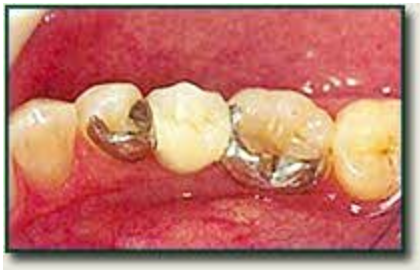

Figure 1. Lingual view of the failing 14-year-old Maryland bridge replacing a missing mandibular second premolar.

The patient also wanted a more aesthetic bridge, but was reluctant to proceed if a significant reduction of the first molar and first premolar was required. A treatment plan using an inlay-retained Sculpture/FibreKor (Jeneric/Pentron) fixed all-ceramic onlay bridge to replace the failing Maryland bridge was presented. Conservative inlay retainer preparations on the mesial of the first molar and the distal of the first premolar was suggested. This treatment plan respected his concerns about minimal tooth reduction, while providing a far more aesthetic prosthesis. A preoperative impression was made using 30-Second Blue Velvet (J. Morita), a thixotropic, vinyl polysiloxane bite registration material. This would later be used as a matrix to make the provisional. Removal of the failing Maryland bridge revealed extensive carious enamel and dentin around and under the metal wings and rest seats. These areas were stained with Caries Detector (J. Morita) to ensure adequate detection. The carious enamel and dentin were more extensive than expected, requiring a modification of the treatment plan. The first premolar was prepared for an MODL onlay. The path of insertion was perpendicular to the occlusal plane and in line with the long axis of the tooth. The axial walls were flared out 10° from the vertical, and all the internal line angles were rounded. Bevels were not placed on any of the cavosurface margins, and the finish line was a deep chamfer. The occlusal surface was reduced almost 3 mm, because of the extent of the carious enamel and dentin. This is a little more than the ideal occlusal reduction for Sculpture/ FibreKor, which should be 2.0 mm.<sup>1</sup> The first molar was prepared for an MODL onlay. The mesial was prepared with a 2-mm wide proximal box, which was incorporated into the lingual reduction, creating a 2-mm wide chamfer and ending in a distal proximal box. A 2-mm wide vertical groove was cut into the lingual groove area. The mesiolingual and distolingual cusps were reduced 2 mm. The path of insertion was aligned with the MODL onlay preparation on the first premolar, making them both parallel. The same basic guidelines used for the MODL onlay preparation on the first premolar were followed with the MODL onlay preparation on the first molar. To ensure patient comfort, Liner Bond 2V (J. Morita) was applied to the preparations after they had been completed. Primer A and B were mixed for 5 seconds in a well and applied with an applicator tip. This was volatilized with gentle blasts of air after 30 seconds. Bond A was applied sparingly with an applicator tip, air thinned, and light cured. By applying the bonding agent at

this time, the dentinal tubules were sealed and the patient felt no discomfort when the anesthesia wore off. When the patient returned for the insertion of the prosthesis, it was not necessary to administer local anesthesia because the dentinal tubules were sealed. As a result, the patient was spared the discomfort of having a second inferior alveolar block. Because of the extent of the carious enamel and dentin, the finish lines of the preparations were extended down to the gingiva. To make an accurate final impression clearly reproducing the finish lines, a quadrant Triple Tray was used (Premier) with the hydraulic and hydrophobic impression technique<sup>2</sup> (Figure 2). This technique was selected because it allowed accurate reproduction of the finish lines without having to pack retraction cord. A flexible cheek retractor to increase access was also placed.

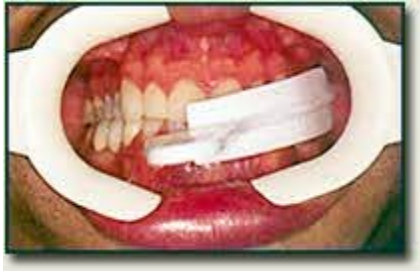

Figure 2. Empty Triple Tray being tried in to check fit.

This is a two-step impression technique relying on the generation of hydraulic pressure to propel impression material into the sulcus and all the internal aspects of the preparations. In the first step, 30-Second Blue Velvet was loaded onto one side of the Triple Tray, which was inserted on the maxillary posterior quadrant. The other side was loaded with the bite registration material (Figure 3). The patient was instructed to close all the way down into MI and hold the position until the material had set.

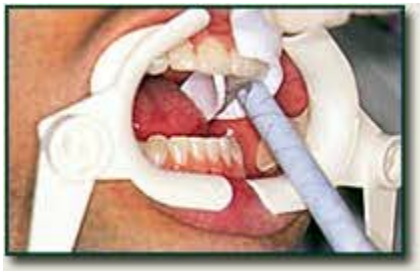

Figure 3. Triple Tray loaded with 30-Second Blue Velvet is inserted on the posterior maxillary quadrant. The mandibular side of the tray is then loaded.

The impression was held against the opposing arch and stabilized. A small amount of 90-Second Flexi-Velvet (J. Morita), a thixotropic, low-viscosity, vinylpolysiloxane material, was injected into each Blue Velvet impression of the first molar and first premolar. It was not injected anywhere else in the impression, nor around the prepared teeth. The patient closed back down into the impression and held that position until the material had set. When the patient closed into the Flexi-Velvet, hydraulic pressure was generated when the material was compressed against the walls of the Blue Velvet impression. Blue Velvet has an 85 Shore A durometer hardness, similar to the characteristics of plaster. The hydraulic pressure generated propelled the low-viscosity Flexi-Velvet into the sulcus around the first molar and first premolar preparations. The low-viscosity material was also propelled into every line angle and internal aspect of the preparations. This produced a highly accurate final impression (Figure 4), which required less than 4 minutes of chair time, eliminated the need for packing retraction cord, and maintained patient comfort.

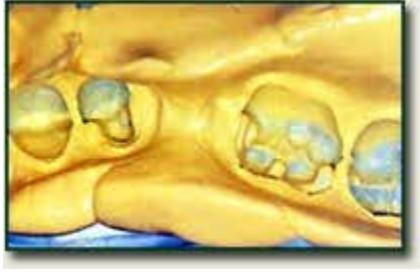

Figure 4. Final impression demonstrating excellent reproduction of margins and detail.

By using the Triple Tray, the need for a separate impression of the opposing arch and a bite registration record were eliminated. The quadrant impression was held up against a light source and examined for perforations in the occlusal surfaces. In many cases, when the patient bites down into MI, several small perforations indicating that these areas were in occlusion during the impression may occur (Figure 5).

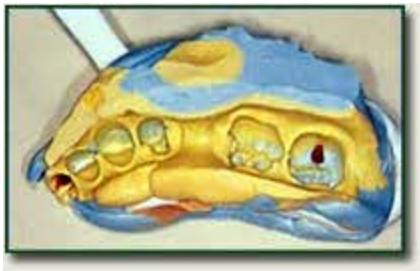


Figure 5. Drops of red wax have been inserted into areas where the occlusal surfaces perforated during the impression procedure.